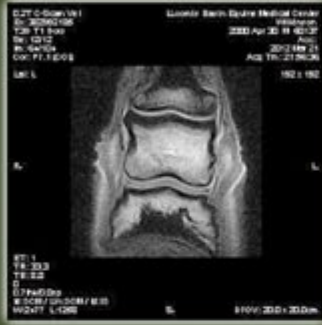



## What is an MRI?

Magnetic resonance imaging (MRI) uses a magnetic field and pulses of radio wave energy to generate images of the structures inside of the horse's leg. We can use it to find problems that cannot be seen with an x-ray or ultrasound. MRI gives us the clearest picture of the problem and enables us to give you a more exact answer.

## LBEMC Services

### SURGERY

- Emergency Colic Surgery
- Arthroscopy
- Laser Surgery
- Airway Surgeries
- Laparoscopy
- Orthopedic and Soft Tissue Surgery

### REPRODUCTION

- Embryo Transfer
- AI- Frozen Semen
- AI – Cooled Semen

### DENTISTRY

- Routine Dental Care
- Tooth Extractions
- Specialized Dental Procedures

### LAMENESS

- Full Spectrum of Diagnostic Testing
- Stem Cell Treatment
- IRAP
- Platelet Rich Plasma Treatment

### EMERGENCY/CRITICAL CARE

- 24 hour/ 365 days a year service
- Ambulatory or Hospital Care
- Intensive Care: Neonatal and Adult

### IMAGING

- MRI: Forelimbs and Hindlimbs
- Digital x-rays: Legs, abdomen, chest, neck, etc.
- Digital ultrasound: Legs, heart, lungs, abdomen
- Endoscopy: Stomach (ulcers), airway, bladder, etc.

### ADDITIONAL SERVICES

- Ophthalmology
- Dermatology
- Acupuncture
- Nutrition
- Behavior

### OTHER SERVICES:

- Oncology (cancer):  
Surgical and Medical Treatment (chemotherapy)
- Laboratory: On site machines with results in 20 minutes
- CT Scan (depending on patient size)
- Pre-purchase Exams



## Loomis Basin Equine Medical Center, Inc.

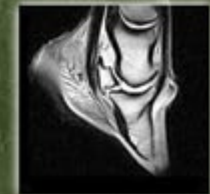
3901 Sierra College Blvd., P.O. Box 2059  
Loomis, CA 95650

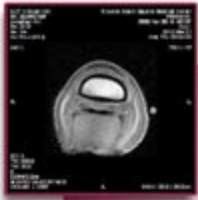(916) 652-7645

[www.lbemc.com](http://www.lbemc.com)



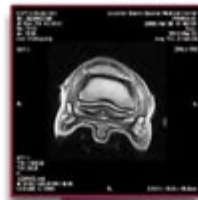# MRI Advantages





## Which horses should have an MRI?

The most common reason for an MRI at our hospital is a lameness that is caused by a problem in the foot. When x-rays cannot identify the reason for the lameness, we recommend an MRI so that we can see all of the tendons and ligaments that are located deep within the foot. Once the MRI has helped us determine which structure is injured, we can help you treat the injury and get your horse back to soundness. The fetlock is probably the next most common region that we image with the MRI and much like the foot, the MRI lets us find injuries that we can't see with x-rays and ultrasound. Suspensory ligament injuries are the third most common reason for an MRI at our clinic. If your horse has developed a lameness, please call or e-mail us and we can help you determine if MRI is the right test for you and your horse. We have made this test a very practical and affordable alternative for people that want an answer to the sometimes frustrating process of lameness in horses.



## How can an MRI assist in healing my horse?

By identifying the precise nature of an injury or degenerative process, the treatment can be perfectly tailored to your horse yielding a better outcome. Many of the advanced treatment options that we have can be performed at the time of the MRI. Once the lesion has been located, we can immediately prepare and use Platelet Rich Plasma to locally treat

a soft tissue injury such as a tendon or ligament tear. If there is damage detected in a specific joint, we can also prepare and use IRAP as an injection into the joint. Stem Cells can be collected and cultured for treatment after the MRI has been completed. Navicular bursa injections can be performed at the time of MRI once the status of the navicular bone and the surrounding structures have been characterized. Targeted rehabilitation programs and exercise plans can be created for your horse based on the exact nature of all areas that are potentially affected within the same leg. By increasing our knowledge of the extent of injury or damage, it puts the power into our hands to use these advanced treatment options to their greatest potential.

